

A 61-year-old man presented with left renal colic pain within 5 days. He had no history of ureteral colic and no family history of renal stone disease. Physical examination revealed left costovertebral angle tenderness and a palpable mass in the left flank region. Roentgenologic examination including direct urinary system graphy showed a left pelvic radiopaque nodule (Figure 1). The serum creatinine level was 1.8 mg/dl. The rest of the laboratory parameters were within normal limits. Computed tomography of the abdomen revealed a left lower ureteral stone (2.5cm) and giant ureterohidronephrosis (Figure 2 A, B, C). He received ureteroscopic lithotripsy and placement of a double-J ureteral stent.

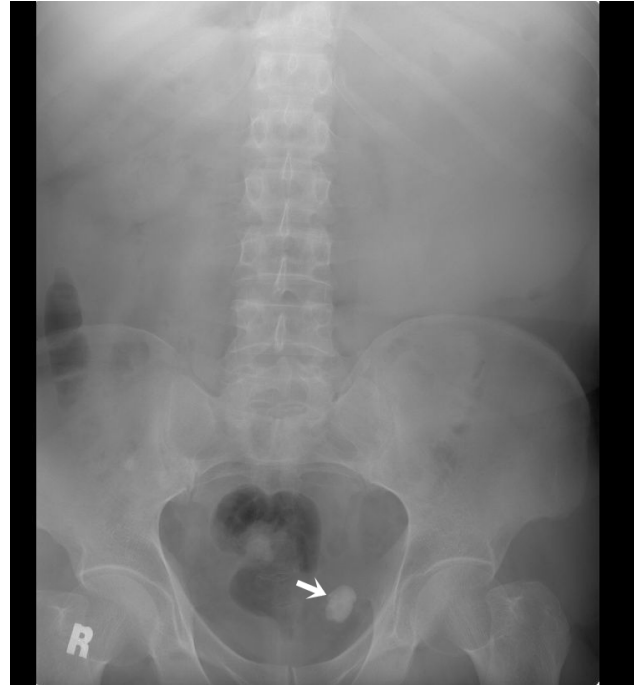


Figure 1. Direct urinary system graphy showing distal left ureteral stone (arrow).

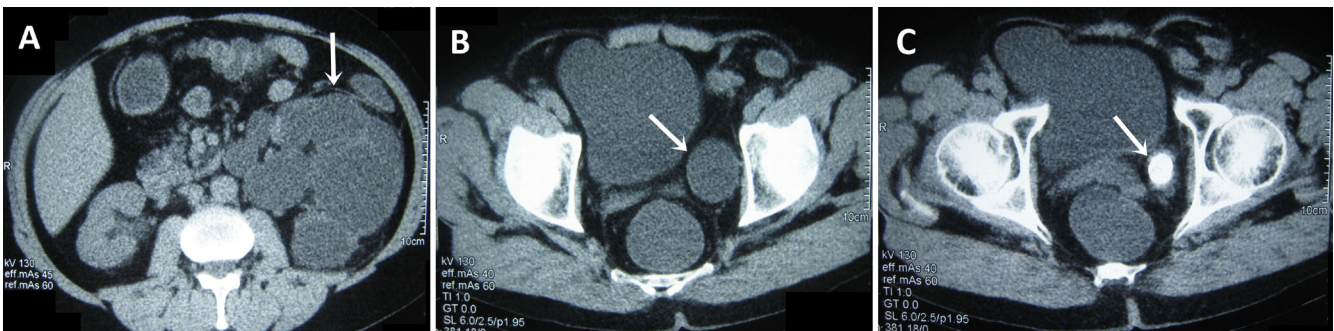


Figure 2. Computed tomography scan of the abdomen revealing giant hydronephrosis (arrow) (A), massive hydroureter (arrow) (B) and distal giant left ureteral stone (arrow) (C).